

PROVISIONAL ANSWER KEY

Question 49/2024/OL

Paper Code:

Category 291/2023

Code:

Exam: Assistant Professor in Oral Medicine and Radiology

Date of Test 03-05-2024

Department Medical Education

Question1:-A 51-year-old man presents with a 9-month history of ulcers in mouth causing discomfort while eating. On examination, there are large blisters on labial mucosa that rapidly bursts. Also, there are eroded skin lesions on his back. No ocular or genital symptoms. Nikolsky sign is positive. The investigation to make definitive diagnosis include

A:-Direct immunofluorescence of perilesional tissue and indirect immunofluorescence of blood stream

B:-Indirect immunofluorescence of perilesional tissue and direct immunofluorescence of blood stream

C:-Indirect immunofluorescence of lesional tissue and direct immunofluorescence of blood stream

D:-Direct immunofluorescence of lesional tissue and indirect immunofluorescence of blood stream

Correct Answer:- Option-A

Question2:-A 50 year old male patient reported to the dental OPD with complaint of recurrent erosions in oral cavity since last 6 months. He also complained of bloodstained nasal discharge, painful lesions in both the eyes with diminished vision for the past 4 months. Oral examination revealed multiple, erythematous, erosive lesions over gingiva, buccal mucosae, soft palate and tongue. Immunofluorescence staining showed autoimmunity against Laminin 332. The condition the patient is likely suffering from

A:-Paraneoplastic pemphigus

B:-Linear IgA disease

C:-Cicatricial pemphigoid

D:-Epidermolysis bullosa acquisita

Correct Answer:- Option-C

Question3:-A 60-year-old male reported with a chief complaint of bleeding gums. He had a history of paroxysmal supraventricular tachycardia, pulmonary embolism, type-2 diabetes mellitus, hypertension, hyperlipidemia and was on metformin, warfarin, atorvastatin and aspirin. Examination revealed BP-140/90mmHg and diffuse gingival bleeding. Which of the following tests would provide a definitive diagnosis ?

A:-Bleeding time

B:-INR-International Normalization Ratio

C:-PTT-Partial Thromboplastin Time

D:-Platelet count

Correct Answer:- Option-B

Question4:-Diagnosis of Lupus erythematosus can be done by lupus band test. It is _____ to reveal _____

A:-Direct immunochemistry; IgM, IgG, IgE and C3

B:-Indirect immunochemistry; IgM, IgG, IgA and C3

C:-Direct immunochemistry; IgM, IgG, IgA and C3

D:-Indirect immunochemistry; IgM, IgG, IgE and C3

Correct Answer:- Option-C

Question5:-A 57-year-old male chronic tobacco chewer presented with an ulceroproliferative growth with indurated margins on left buccal mucosa. Which of the following genetic markers play a crucial role in the carcinogenesis ?

A:-Tumor suppressor genes such as bcl-1 and PRAD-1

B:-Tumor suppressor genes such as p-16 and p53

C:-Tumor suppressor genes such as bcl-1 and Int-2

D:-Tumor suppressor genes such as H-ras and PRAD-1

Correct Answer:- Option-B

Question6:-A 12 year old female reported with a swelling in left cheek region, Intraorally, large soft tissue mass was evident in left buccal mucosa. Incisional biopsy revealed features suggestive of rhabdomyosarcoma with clusters of small round cells. Immunohistochemistry of which below marker is specific for this condition ?

A:-Podoplanin

B:-Desmin

C:-S-100

D:-Cytokeratin

Correct Answer:- Option-B

Question7:-A 30 year old female patient reported with chief complaint of altered taste in mouth. She also stated reduction in the intensity of taste perception. Which is one of the recent investigative method to observe the nature of tongue papillae ?

A:-Isotope scanning

B:-Microendoscopy

C:-Cineradiography

D:-Videomicroscopy

Correct Answer:- Option-D

Question8:-A 4 year old male child was brought to dental OPD in view of red and white patches in the mouth. General examination revealed dysplastic nails, reticular pattern of skin hyperpigmentation evident on the face and neck. Intraorally, there were areas of erosive lesions interspersed within leukoplakic

lesions in buccal mucosa. Genetic testing revealed mutation in DKC1 gene. Which is the first hematological sign seen in this patient ?

A:-Anemia

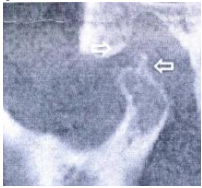
B:-Polycythemia

C:-Thrombocytopenia

D:-Erythrocyte sedimentation rate

Correct Answer:- Option-C

Question9:-A 45 year old male patient reports with pain and crepitus in left TMJ with restricted mouth opening and tenderness on palpation. There is shift of mandible towards left side. The CBCT shows new bone suggestive of osteophytes on the superior surface of condyle. Which of the following investigation is specific for this patient ?



A:-ANA (Antinuclear Antibody)

B:-ANCA (Antineutrophil Cytoplasmic Antibodies)

C:-ACPA (Antibodies to Citrullinated Proteins)

D:-Anti-topoisomerase I (anti-Scl-70) antibody

Correct Answer:- Option-C

Question10:-A 24-year-old female presents with headache, anorexia, chills, with discomfort on both sides of her jaw. Physical examination reveals bilaterally enlarged parotid glands, elevating the ear lobule, that are doughy, elastic, and slightly tender. Papilla of the parotid duct on the buccal mucosa is puffy and reddened. Her abdomen is soft with bilateral lower quadrant abdominal tenderness. A temperature of 38.5°C; and a pulse rate of 92/min. Hemoglobin 13 g/dL; White Blood Cells (WBC) 9000/mL, with 35% segmented neutrophils, 7% monocytes, and 58% lymphocytes. Which of the following is the most likely diagnosis ?

A:-Parotid sialosis

B:-Mumps

C:-Sjogren syndrome

D:-Warthin's tumor

Correct Answer:- Option-B

Question11:-A 17-year-old male presents with tooth ache in right mandibular region. Gives 1-week history of malaise and anorexia followed by fever and sore throat. On physical examination, cervical lymphadenopathy was present and the liver and the spleen were palpable. On intraoral examination, few palatal petechiae and inflamed throat with no evidence of exudate were observed. Throat culture was negative for group A streptococci. Blood work revealed WBC : 14,000/ μ L; Lymphocytes: 60%; Monocytes: 10%; Bilirubin total: 2.0 mg/dL; AST: 40 U/L (normal 8 to 20 U/L); ALT: 35 U/L (normal 8 to 20 U/L). The diagnostic test is

A:-Hepatitis B IgM

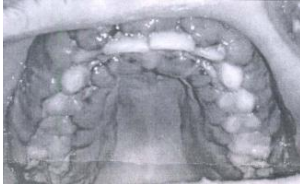B:-Hepatitis B IgG

C:-Heterophile antibody

D:-ASO titre

Correct Answer:- Option-C

Question12:-A 32 year-old male patient reported to OPD with chief complaint of swollen gums. On examination, extensive hemorrhagic enlargement of maxillary and mandibular gingivae was observed. Poorly differentiated leukemic cells seen in peripheral blood and bone marrow.



Most probable diagnosis will be

A:-Chronic myeloid leukemia

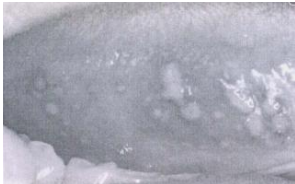B:-Acute lymphoid leukemia

C:-Kaposi's sarcoma

D:-Cyclic neutropenia

Correct Answer:- Option-A

Question13:-A 30-year old male reported with chief complaint of recurrent ulcers in mouth. History of burning sensation during micturition. Skin lesions revealed scattered, tender erythematous nodules. Intraorally, numerous irregular areas of ulcerations of the ventral surface of the tongue noted.



The most likely diagnostic test for this condition will be

A:-Erythrocyte sedimentation rate

B:-Intradermal patch test

C:-Pathergy test

D:-Kviem test

Correct Answer:- Option-C

Question14:-A patient was clinically diagnosed with oral candidiasis. Smear from infected area was obtained. Which additional examination can be done to discriminate between different candidal species ?

A:-Imprint culture technique

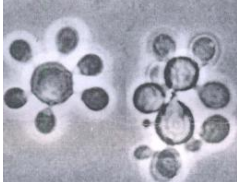
B:-Sabouraud agar

C:-Pagano-Levin agar

D:-Periodic Acid - Schiff (PAS)

Correct Answer:- Option-C

Question15:-A 45 year old male presented with symptoms of fever and ulcers on nose, mouth including tongue, pharynx and gums. Microscopic examination shows thick walled cells that form the classical 'Steering Wheel' or 'Mickey Mouse' structures that are diagnostic of the fungus. Most probable diagnosis



A:-Candidiasis

B:-Gilchrist disease or North American blastomycosis

C:-Paracoccidioidomycosis

D:-Mucormycosis

Correct Answer:- Option-C

Question16:-Patient presents with squamous cell carcinoma involving left buccal mucosa measuring 4 cm in diameter, 6 cm ipsilateral lymph node with lung metastasis, the TNM staging of this patient would be

A:-Stage III

B:-Stage IVA

C:-Stage IVB

D:-Stage IVC

Correct Answer:- Option-D

Question17:-In Oncology practice, various bone-modifying agents are commonly used to reduce the risk of skeletal bone fracture in patients with skeletal metastatic disease. Which class of agents are used under this category ?

A:-Bisphosphonates

B:-Antiangiogenics

C:-Denosumab

D:-All of the above

Correct Answer:- Option-D

Question18:-Which one of the following is a tool of medication assessment to evaluate polypharmacy in elderly patients to improve patient's functional status and mobility ?

A:-ARMOR

B:-SOAP

C:-IMPT

D:-NSD

Correct Answer:- Option-A

Question19:-A 12 year old boy reports with his mother for missing and malaligned teeth. On extraoral examination, there is frontal and parietal bossing with

brachycephalic skull. On intraoral examination, there is evidence of retained maxillary and mandibular deciduous molar and absence of permanent premolars. PA skull revealed multiple wormian bones. Chest X-ray shows hypoplasia of bilateral clavicles. OPG shows multiple impacted supernumerary teeth in both the jaws. What is the diagnosis for this condition and the underlying pathology ?

- A:-Cleidocranial dysostosis, mutation in TCOF1 gene
 - B:-Crouzon syndrome, mutation in FGFR2 gene
 - C:-Treacher Collin syndrome, mutation in TCOF1 gene
 - D:-Cleidocranial dysplasia, mutation in Runx2 gene
- Correct Answer:- Option-D

Question20:-Constellation of localized pain, motor and sweat abnormalities and trophic changes in soft tissues of muscle and skin is known as

- A:-Regional sympathetic dystrophy
- B:-SUNCT
- C:-Chronic paroxysmal hemicrania
- D:-Hemicrania continua

Correct Answer:- Option-A

Question21:-A 30 year old female reported with painless swelling of lower jaw since 10-15 days. On intraoral examination, a well circumscribed, bony hard swelling was evident over lingual surface of right body of mandible. On mandibular occlusal radiograph, circumscribed, round radiolucent lesion with a small central radiopacity was seen attached to the lingual cortex in region of mandibular 1st molar. What is the most probable diagnosis ?

- A:-Osteoid osteoma
- B:-Osteosarcoma
- C:-Cementoblastoma
- D:-Condensing osteitis

Correct Answer:- Option-A

Question22:-A 32-year-old woman presented with history of fatigue since 9 months and progressive difficulty in swallowing solids for 2 months. On examination, she was pale and had glossitis, cheilitis, and koilonychia. Blood picture revealed microcytic hypochromic anemia with anisocytosis. Laboratory investigations showed hemoglobin level of 6 g/dL and raised total iron-binding capacity. The most probable diagnosis for this condition is

- A:-Polycythemia vera
- B:-Paterson Kelly syndrome
- C:-Iron deficiency anemia
- D:-G-6-P deficiency

Correct Answer:- Option-B

Question23:-A 43 year old female presented with 5 mm diameter ill defined pigmented macule at interdental gingiva between maxillary left lateral incisor and

canine which she observed few days back. She gave recent history of trauma due to impingement of fish bone in the same region. No other abnormal finding was present. On biopsy, there was proliferation of benign dendritic melanocytes throughout spongiotic epithelium with mild lymphocytic infiltrate. Lesion healed following biopsy. What could be the probable diagnosis ?

A:-Pigmented nevus

B:-Melanotic macule

C:-Melanoma

D:-Melanoacanthoma

Correct Answer:- Option-D

Question24:-A 20 year old female complains of multiple lumps on her gums and cheek for past few months. She presented with recent abnormalities in her menstrual cycle for which she was undergoing gynecological examination and ultrasound revealed multiple ovarian masses. Clinically multiple papillomatous lesions were appreciated in lips, gingiva and palate. What is your most probable diagnosis ?

A:-Cowden's syndrome

B:-Gorlin syndrome

C:-Neurofibromatosis

D:-Tuberous sclerosis

Correct Answer:- Option-A

Question25:-A 50-year-female presented with history of asymptomatic pigmented spots on tongue, lower lip, fingers, and toes which had developed gradually over last 2 years. There was no family history of similar skin disease. Clinical examination revealed brown colored pigmented macules 1-3 mm in size. Examination of hands revealed round to oval well-defined brown-colored macules 1-5 mm in diameter on the palmar aspect of the tips of all the fingers. Laboratory investigations showed a hemoglobin value of 11.2 gm%. ESR was raised to 42 mm/h. Biopsy showed no increase in the number of melanocytes and no junctional activity or melanin incontinence. Further examination showed no systemic abnormality. The patient is most likely a case of

A:-Neurofibromatosis

B:-Laugier Hunziker syndrome

C:-Addison's disease

D:-Fibrous dysplasia

Correct Answer:- Option-B

Question26:-Which of the following drug regimens for systemic use need not be changed in patients with chronic renal failure ?

A:-Metronidazole

B:-Codeine

C:-Ketorolac

D:-Diphenhydramine

Correct Answer:- Option-B

Question27:-Which amongst the following is a contraindication for the use of Pilocarpine ?

A:-Gastroesophageal Reflux Disease (GERD)

B:-Diabetes Mellitus

C:-Fibromyalgia

D:-Uncontrolled Asthma

Correct Answer:- Option-D

Question28:-A 15 year old male complains of spontaneous bleeding episodes from gums. He gives a history of prolonged bleeding after minor bruise. His routine hematologic tests are within normal limits. Various laboratory tests for assessing hemostasis like bleeding time, PT/INR, aPTT and platelet count are also within normal range. Which of the following disorders is the most probable cause ?

A:-von Willebrand disease

B:-Factor XIII deficiency

C:-Severe Liver disease

D:-Vascular wall defect

Correct Answer:- Option-B

Question29:-A 40 year old female complains of recent onset fatigue, decreased mental concentration, dysphagia and burning sensation of the tongue. Clinically she presented with inflamed tip and margins of tongue with papillary atrophy. Which of the following interpretations will determine the diagnosis ?

A:-Raised MCV, Normal MCH, Raised MCHC, Low Hemoglobin

B:-Low MCV, Raised MCH, Normal MCHC, Raised Hemoglobin

C:-Low MCV, Normal MCH, Raised MCHC, Raised Hemoglobin

D:-Raised MCV, Raised MCH, Normal MCHC, Low Hemoglobin

Correct Answer:- Option-D

Question30:-A 60 year old female complains of burning sensation of mouth while taking spicy foods. She is also reporting pain in knees, facial skin eruptions and malar rash for past few months. Intraorally multiple erythematous and ulcerative lesions are appreciated over bilateral buccal mucosa and tongue. Which of the following serological examinations will help in diagnosis of the condition ?

A:-ANA, anti ds DNA, anti U1 RNP, anti phospholipids

B:-ANA, ANCA, anti U1 RNP

C:-ANA, anti Th/To, anti Pm/ Scl

D:-ANA, RF, Anti CCPs

Correct Answer:- Option-A

Question31:-Lesions strongly associated with HIV infection are all except

A:-Kaposi sarcoma

B:-Linear gingival erythema

C:-Hairy leukoplakia

D:-Mycobacterium tuberculosis infection

Correct Answer:- Option-D

Question32:-In leukemia patients undergoing haematopoietic cell transplant, chronic GVHD may be considered beneficial because of the following reason

A:-Oral cavity is not involved

B:-Immunologic process eliminates persistent leukemic cells

C:-Inflammatory reactions are suppressed

D:-Risk of infection is reduced

Correct Answer:- Option-B

Question33:-In some HIV patients, HAART-induced immune recovery results in a spectrum of presentations ranging from clinical worsening of established opportunistic infection and the appearance of new opportunistic infections to autoimmune disorders. This phenomenon is also known as

A:-Rebound immunity syndrome

B:-Targeted HAART induced immunity

C:-Immunity suppression

D:-Immune reconstitution inflammatory syndrome

Correct Answer:- Option-D

Question34:-Platelet transfusions are the main treatment modality for which of the following disorders ?

A:-von Willebrand disease

B:-Hemophilia A

C:-Bernard-Soulier syndrome

D:-Rendu-Osler-Weber syndrome

Correct Answer:- Option-C

Question35:-OraQuick is a test for which of the following infections ?

A:-HIV

B:-HBV

C:-HSV

D:-HPV

Correct Answer:- Option-A

Question36:-Which of the following are the surrogate tests to assess folate and vitamin B_{12} levels ?

A:-Homocysteine and methylmalonic acid levels

B:-NADP and histidine levels

C:-Pepsin and lipase levels

D:-Enterokinase and gastrin levels

Correct Answer:- Option-A

Question37:-The cardiac conditions associated with the highest risk of adverse outcomes from endocarditis for which antibiotic prophylaxis with dental procedures is recommended are all except

- A:-Prosthetic cardiac valve or prosthetic material used for cardiac valve repair
- B:-History of infectious endocarditis
- C:-Coronary artery disease
- D:-Unrepaired cyanotic congenital heart disease

Correct Answer:- Option-C

Question38:-A patient with sickle cell anemia may develop sequestration syndrome which can involve all the following organs with respective disorders except

- A:-Lungs (chest syndrome)
- B:-Spleen (septicaemia)
- C:-Liver (girdle syndrome)
- D:-Brain (encephalopathy)

Correct Answer:- Option-D

Question39:-Which of the following is a long acting type of insulin ?

- A:-Lente
- B:-Ultralente
- C:-Lispro
- D:-Neutral Protamine Hagedorn

Correct Answer:- Option-B

Question40:-Following are the components of fresh frozen plasma except

- A:-Factor II
- B:-Factor VII
- C:-Factor VIII
- D:-Factor XI

Correct Answer:- Option-C

Question41:-A 50-year-old female complains of pain on the Right side of her lower jaw for the past 25 days. The patient gives a history of extraction of the mandibular right third molar 2 months back. Pain is moderate in intensity, described as burning and persistent in nature. On examination, there is no significant pathology evident on both clinical as well as radiological examination. The most likely diagnosis of the above condition is

- A:-Post herpetic neuralgia
- B:-Post traumatic trigeminal neuropathy
- C:-Sphenopalatine neuralgia
- D:-Burning mouth syndrome

Correct Answer:- Option-B

Question42:-A 45 year old male complains of severe stabbing and burning pain on left side malar prominence region which is triggered by touching face and innocuous stimuli. They remain for very short period and there is no fixed pattern of repetition. It is always associated with lacrimation, redness of eyes and eyelid edema. What is your probable diagnosis ?

A:-SUNCT

B:-Hemicrania continua

C:-Causalgia

D:-Trigeminal Neuralgia

Correct Answer:- Option-A

Question43:-In which of the following TMJ disorders, there is history of chronic TMJ click with intermittent locking of TMJ. The first-time occurrence of acute lock is associated with pain, which increases on mouth opening although mouth opening is severely reduced. Further, mandible deviates to affected side and limited lateral movement to contralateral side.

A:-Anterior disc displacement with reduction

B:-Anterior disc displacement without reduction (Acute closed lock)

C:-Anterior disc displacement with intermittent locking

D:-Anterior disc displacement without reduction (Chronic closed lock)

Correct Answer:- Option-B

Question44:-Which of the following conditions is characterized by the presence of tender points in specific areas of the face and neck, often associated with widespread musculoskeletal pain ?

A:-Local muscle soreness

B:-Muscle splinting

C:-Myospasm

D:-Fibromyalgia

Correct Answer:- Option-D

Question45:-Which of the following are normal range of maximum mouth opening and lateral/protrusive movements ?

A:- ≥ 40 mm, ≥ 5 mm respectively

B:- ≥ 30 mm, ≥ 7 mm respectively

C:- ≥ 30 mm, ≥ 5 mm respectively

D:- ≥ 40 mm, ≥ 7 mm respectively

Correct Answer:- Option-D

Question46:-Which of the following is not generally recommended for the management of Burning Mouth Syndrome ?

A:-Alpha lipoic acid

B:-Tramadol

C:-Paroxetine

D:-Clonazepam

Correct Answer:- Option-B

Question47:-A 45 year old male complains of scratching or foreign body sensation in the throat. He gets sharp shooting, lancinating pain at the base of tongue region as well as pharyngeal region which radiates to ear. Pain event subsides on its own in around 2 min. Such episodes occur three to four times daily. The pain gets aggravated especially while swallowing, chewing, talking, coughing and/or yawning, sneezing etc. The patient's CT image of neck region was normal without any pathology. What is your probable diagnosis ?

A:-Occipital Neuralgia

B:-Postherpetic Neuralgia

C:-Glossopharyngeal Neuralgia

D:-Sphenopalatine Neuralgia

Correct Answer:- Option-C

Question48:-In which of the following tests, the patient is asked to open mandible slightly and to keep remain in one position, while the patient resists the slowly increasing manual force applied by the examiner in each of right lateral, left lateral, upward and downward directions ?

A:-Unilateral loading via clench

B:-Bilateral loading via clench

C:-Dynamic muscle contraction test

D:-Static muscle contraction test

Correct Answer:- Option-D

Question49:-In which of the following conditions, there is facial asymmetry, the chin may deviate to the unaffected side, or it may remain unchanged but with an increase in the vertical dimension of the ramus, mandibular body, or alveolar process of the affected side. As a result of this growth pattern, patients may have a posterior open bite on the affected side or a crossbite on the contralateral side ?

A:-Condylar hyperplasia

B:-Condylar hypoplasia

C:-Coronoid hyperplasia

D:-Coronoid hypoplasia

Correct Answer:- Option-A

Question50:-Which of the following disorders could be prevented by use of vaccine especially in old age people ?

A:-Trigeminal neuralgia

B:-Post herpetic neuralgia

C:-Glossopharyngeal neuralgia

D:-Cluster headache

Correct Answer:- Option-B

Question51:-Purely serous salivary gland

A:-Glands of Weber

B:-Submandibular gland

C:-Sublingual gland

D:-von Ebner's gland

Correct Answer:- Option-D

Question52:-Indicator of oral dryness

A:-Lipstick sign

B:-Asboe-Hansen sign

C:-Gorlin sign

D:-Auspitz sign

Correct Answer:- Option-A

Question53:-The following salivary gland imaging modality is used for detecting perineural spread

A:-Sialography

B:-Cone Beam Computed Tomography

C:-Magnetic Resonance Imaging

D:-Sialoendoscopy

Correct Answer:- Option-C

Question54:-A benign, self-limiting, reactive inflammatory disorder most frequently affecting minor salivary glands

A:-Mucocele

B:-Necrotizing Sialometaplasia

C:-Sialolith

D:-Ranula

Correct Answer:- Option-B

Question55:-Medications causing hypersalivation

A:-Cholinergics

B:-Cytotoxic agents

C:-Antihistamines

D:-Antidepressants

Correct Answer:- Option-A

Question56:-X rays were discovered by Wilhelm Conrad Roentgen in which year ?

A:-1895 November 6

B:-1896 November 6

C:-1895 November 8

D:-1896 November 8

Correct Answer:- Option-C

Question57:-The total filtration in the path of a x ray beam for a dental x ray machine operating up to 70 kVp to be equal to the equivalent of

A:-0.5 mm of aluminum

B:-1.5 mm of aluminum

C:-2.5 mm of aluminum

D:-1.5 mm of lead

Correct Answer:- Option-B

Question58:-Photons in an x ray beam interact with the object, the following occurs

A:-Compton scattering 7%

B:-Coherent scattering 9%

C:-Photoelectric absorption 27%

D:-Within or pass through the object without interaction 57%

Correct Answer:- Option-C

Question59:-One of the most significant naturally occurring radioactive elements in the earth's crust

A:-Copper

B:-Lead

C:-Polonium

D:-Uranium

Correct Answer:- Option-D

Question60:-The emission spectrum in the intensifying screens, where phosphor crystals contain rare earth elements of terbium activated gadolinium oxysulfide

A:-Ultraviolet Light

B:-Blue Light

C:-Green Light

D:-Red Light

Correct Answer:- Option-C

Question61:-Restrainer in processing solution

A:-Maintains an alkaline pH

B:-Serves as the electron donor

C:-Dissolves the unexposed silver halide grains

D:-Acts as antifog agents

Correct Answer:- Option-D

Question62:-The amount of radiation required to produce an image of a standard

density

A:-Radiographic Resolution

B:-Radiographic Contrast

C:-Radiographic Speed

D:-Radiographic Mottle

Correct Answer:- Option-C

Question63:-In Submentovertex radiographic projection

A:-The patient's head is tilted upward so that the canthomeatal line forms a 37-degree angle with the image receptor

B:-The patient's neck is extended as far backward as possible, with the canthomeatal line parallel to the image receptor

C:-The patient's canthomeatal line forms a 10-degree angle with the horizontal plane and the Frankfurt plane and is perpendicular to the image receptor

D:-The patient's head is tilted downward so that the canthomeatal line forms a 30-degree angle with the image receptor

Correct Answer:- Option-B

Question64:-A safelight mounted on the wall or ceiling in the x ray film processing darkroom

A:-2 feet from the work surface

B:-3 feet from the work surface

C:-4 feet from the work surface

D:-6 feet from the work surface

Correct Answer:- Option-C

Question65:-The image frequently seen on periapical radiographs of the maxillary molar region as a triangular radiopacity, with apex directed superiorly and anteriorly and superimposed on the region of the third molar

A:-Coronoid process of the mandible

B:-Floor of Maxillary sinus

C:-Maxillary tuberosity

D:-Zygomatic arch

Correct Answer:- Option-A

Question66:-In photostimulable phosphor plates material used for radiographic imaging

A:-Gadolinium

B:-Selenium

C:-Europium-doped barium fluorohalide

D:-Calcium tungstate

Correct Answer:- Option-C

Question67:-In radiographic appearance pulp chambers are large, the root canals are wide and the tooth appears as a thin shell of hypoplastic enamel and dentin

- A:-Amelogenesis Imperfecta
- B:-Dentinogenesis Imperfecta
- C:-Dentin Dysplasia
- D:-Regional Odontodysplasia

Correct Answer:- Option-D

Question68:-The multiple radiolucencies appearing as depressions of the inner surface of the cranial vault, which results in a beaten metal or copper appearance seen in

- A:-Mandibulofacial Dysostosis
- B:-Craniofacial Dysostosis
- C:-Cleidocranial Dysplasia
- D:-Hemimaxillofacial Dysplasia

Correct Answer:- Option-B

Question69:-The imaging method of choice for assessment of space occupying lesions like cyst and neoplasm's of the salivary glands

- A:-Sialography
- B:-Cone Beam Computed Tomography
- C:-Magnetic Resonance Imaging
- D:-Plane Radiography

Correct Answer:- Option-C

Question70:-An inverted pear or tear shaped, well-defined radiolucency between the separated roots of the maxillary lateral incisor and canine suggestive of

- A:-Dentigerous Cyst
- B:-Globulomaxillary Cyst
- C:-Incisive Canal Cyst
- D:-Traumatic Bone Cyst

Correct Answer:- Option-B

Question71:-In nuclear medicine radionuclide imaging uses radioactive atoms or molecules that emit

- A:-Ultraviolet light
- B:-Neutrons
- C:-Visible light
- D:-Gamma rays

Correct Answer:- Option-D

Question72:-Round to oval radiolucent area located above the mandibular canal with well-defined borders and the superior border extends between the roots of the

teeth giving a scalloped appearance seen in

A:-Periapical Cyst

B:-Stafne's Cyst

C:-Traumatic Bone Cyst

D:-Dentigerous Cyst

Correct Answer:- Option-C

Question73:-Radiographic appearance characterized by an increased density of the entire skeleton resulting in sclerotic appearance and bone may appear dense on a dental radiograph that the roots of the teeth are obscured in

A:-Osteoporosis

B:-Osteosarcoma

C:-Osteopetrosis

D:-Multiple Myeloma

Correct Answer:- Option-C

Question74:-The ultrasound signal transmitted into a patient is attenuated by a combination of following except

A:-Ionization

B:-Diffusion

C:-Reflection

D:-Absorption

Correct Answer:- Option-A

Question75:-The common radiographic appearance of generalized increase in the width of the periodontal ligament spaces around the teeth and unusual pattern of mandibular erosive bone changes seen in

A:-Ameloblastoma

B:-Acromegaly

C:-Cherubism

D:-Scleroderma

Correct Answer:- Option-D

Question76:-A 30-year-old pregnant female with history of hyperthyroidism complains of unilateral facial swelling, anosmia and visual disturbance. On examination, patient is noted to have flat pigmented spots on the back. Radiograph of the facial swelling shows ground glass appearance of bone. What is the possible diagnosis ?

A:-Neurofibromatosis

B:-Osteogenesis imperfecta

C:-McCune-Albright Syndrome

D:-Fibrous Dysplasia (Jaffe type)

Correct Answer:- Option-C

Question77:-40-year-old male reported after motor vehicular accident. On examination he was noted to have right eye circumorbital ecchymosis, flattening of right cheek, right infraorbital rim tenderness and step deformity. Radiographs that will best demonstrate the fractures are

A:-Lateral Ceph and OPG

B:-Waters view and SMV

C:-OPG and Transcranial

D:-Lateral Oblique and SMV

Correct Answer:- Option-B

Question78:-Radiographic bony change that helps to differentiate between Langerhans' cell Histiocytosis lesion from periodontal disease on an OPG view is

A:-Periphery and margin of the lesion

B:-Epicenter of the lesion

C:-Radiodensity of the lesion

D:-Internal structure of the lesion

Correct Answer:- Option-B

Question79:-A 35-year-old female reported with complaint of loose teeth and joint pain. OPG shows radiopaque teeth standing out in contrast to radiolucent jaws, loss of lamina dura. A single well-defined radiolucency noted in maxillary anterior region of bone histologically diagnosed as giant cell granuloma. What screening tests are to be performed in the following case ?

A:-Fasting Blood Sugar level

B:-Complete Blood Count

C:-Total Iron Binding Capacity

D:-Serum Calcium, PTH and alkaline phosphatase levels

Correct Answer:- Option-D

Question80:-A radiologist is asked to evaluate a series of radiographs of a 60 year old male. OPG shows cotton wool appearance with spacing of teeth, hypercementosis of teeth and B/L maxillary sinuses appear clear. Lateral skull view shows increased density and dimension of skull and jaw bones. The most likely diagnosis is

A:-Fibrous Dysplasia

B:-FCOD

C:-Paget's Disease

D:-Osteomyelitis

Correct Answer:- Option-C

Question81:-Which of the following statements are TRUE about Oral Hypoglycemics ?

i. Metformin suppresses hepatic gluconeogenesis.

ii. Thiazolidinedione agents increase tissue sensitivity to insulin and decrease hepatic gluconeogenesis.

- iii. Acarbose stimulates pancreatic insulin secretion.
- iv. Sulfonylureas provoke release of insulin from pancreas.

A:-i, ii and iv

B:-All of the above

C:-ii and iii

D:-iii and iv

Correct Answer:- Option-A

Question82:-A 35-year-old patient with history of severe Hemophilia A, needs to undergo extraction of mandibular wisdom tooth. What is the most important precaution to be taken prior to the procedure ?

A:-Prophylactic factor replacement

B:-Use of anesthetic solution without vasoconstrictor

C:-Use of oral warfarin prior to the procedure

D:-Use of Ethamsylate prior to the procedure

Correct Answer:- Option-A

Question83:-A 60-year-old asthmatic patient using inhalational corticosteroid, reports with oral burning sensation and an erythematous lesion on palate and tongue dorsum.

What line of treatment is most likely to relieve the symptoms ?

A:-Stopping the medication for asthma

B:-Prescription of antibiotics

C:-Prescription of antifungal medication

D:-Prescription of antiviral medication

Correct Answer:- Option-C

Question84:-A 45-year-old male patient reported with soreness of jaw muscles, on examination, patient shows sign of severe attrition of teeth. He was treated with botulinum toxin in masseter muscle every 5 months. This treatment helped relieve the symptoms by

A:-Increased relaxation of jaw opening muscles

B:-Exerting paralytic effect on the muscle by inhibiting the release of Acetylcholine at the neuromuscular junction

C:-Increasing the vertical dimension of the face

D:-Exerting postsynaptic dopaminergic effect

Correct Answer:- Option-B

Question85:-What precautions need to be taken while prescribing the drug Ketorolac ?

A:-Not to use the medication for longer than 5 days

B:-Not to use for preanesthetic medication

C:-Not to prescribe it to patients on oral anticoagulants

D:-All of the above

Correct Answer:- Option-D

Question86:-Dermatitis, Diarrhea and Dementia is noted in deficiency of which Vitamin ?

A:-Pyridoxine

B:-Niacin

C:-Thiamine

D:-Ascorbic acid

Correct Answer:- Option-B

Question87:-Which of the following is NOT TRUE about HIV treatment guidelines ?

A:-PEP (Post Exposure Prophylaxis) helps to suppress the viral replication prior to dissemination of the infection

B:-Breast feeding by HIV positive patient should be discouraged

C:-While changing a failed HIV regimen, one should replace only a single drug from the failed regimen

D:-Monotherapy (use of single antiviral) in HIV infection is contraindicated

Correct Answer:- Option-C

Question88:-Which of the following drug CANNOT be used for treating Chronic Orofacial pain ?

A:-Pregabalin

B:-Lamotrigine

C:-Amitriptyline

D:-Imipenem

Correct Answer:- Option-D

Question89:-Which one of the following is the least likely indication for antibiotic prophylaxis to prevent Bacterial Endocarditis ?

A:-Congenital Heart Disease

B:-Diabetes Mellitus

C:-Previous History of endocarditis

D:-Rheumatic Heart Disease

Correct Answer:- Option-B

Question90:-Which is the first line antiepileptic drug that can be used for diagnosis and management of Trigeminal Neuralgia ?

A:-Baclofen

B:-Phenytoin

C:-Carbamazepine

D:-Sodium Valproate

Correct Answer:- Option-C

Question91:-The diagnosis process (case history and examination) helps a Dentist to

- i. Recognize deviation from normal general health status that may affect dental treatment.
- ii. Identify need for medical consultation for further management.
- iii. Make informed judgement on risk of dental procedures.
- iv. Completely diminish the need for use of emergency drugs during dental procedures.

A:-i and ii

B:-All of the above

C:-i, ii and iii

D:-i, iii and iv

Correct Answer:- Option-C

Question92:-In American Society of Anesthesiologists classification of physical status of patient, ASA-V indicates

A:-A normal healthy patient

B:-A moribund patient who is not expected to survive without the operation

C:-A declared brain dead patient whose organs are being removed for donor purposes

D:-A patient with severe systemic disease

Correct Answer:- Option-B

Question93:-Following nail changes may be noted in a patient with iron deficiency anemia

A:-Koilonychia and vertical ridging

B:-Thick nails

C:-Splinter hemorrhages

D:-Discoloration of nails

Correct Answer:- Option-A

Question94:-A 70-year-old male patient presented with a non-healing oral ulcer on right lateral border of tongue from a sharp tooth in relation. On examination the ipsilateral submandibular lymph node is enlarged, hard and fixed. The likely diagnosis for the ulcer is

A:-Tuberculous ulcer

B:-Syphilitic ulcer

C:-Malignant ulcer

D:-Traumatic ulcer

Correct Answer:- Option-C

Question95:-A 34-year-old female who presented with toothache to the dental OPD showed following signs on general examination.

1. Anterior neck swelling
2. Tachycardia

3. Tremors of fingers

4. Positive Von Graefe's sign (upper eyelid lags behind the eyeball on looking down)

Patient is most likely to have systematic history of

A:-Ranula

B:-Primary toxic goiter

C:-Branchial cleft cyst

D:-Asthma

Correct Answer:- Option-B

Question96:-FDA cleared use of Toluidine blue staining to evaluate the mucosa for potential malignancy in combination with

A:-Diascopy

B:-Chemiluminescent light device

C:-Lugol's iodine test

D:-Exfoliative cytology

Correct Answer:- Option-B

Question97:-On performing Sialometry, the salivary gland hypofunction may be diagnosed when

A:-Unstimulated salivary flow rate is less than 1 mL/min and stimulated salivary flow rate is less than 7 mL/min

B:-Unstimulated salivary flow rate is less than 0.1 mL/min and stimulated salivary flow rate is less than 0.7 mL/min

C:-Unstimulated salivary flow rate is less than 0.1 mL/min and stimulated salivary flow rate is less than 1 mL/min

D:-Unstimulated salivary flow rate is less than 0.01 mL/min and stimulated salivary flow rate is less than 1.5 mL/min

Correct Answer:- Option-B

Question98:-Chairside Test to differentiate vascular lesion from pigmented lesion would be

A:-VELscope

B:-Diascopy

C:-Endoscopy

D:-Transillumination test

Correct Answer:- Option-B

Question99:-Which is the best imaging modality to evaluate joint effusion in TMJ disc displacement with reduction ?

A:-TMJ arthrography

B:-Magnetic Resonance Imaging

C:-Transcranial view of TMJ

D:-CT Scan

Correct Answer:- Option-B

Question100:-A 25 year old female undergoes extraction of impacted mandibular third molar and is now suffering from loss of taste sensation from the anterior two thirds of tongue. Which nerve is likely to be damaged ?

A:-Lingual nerve

B:-Hypoglossal nerve

C:-Vagus nerve

D:-Glossopharyngeal nerve

Correct Answer:- Option-A